PAUS
Pet Animal Ultrasound Service
4paus.com 781-635-5677

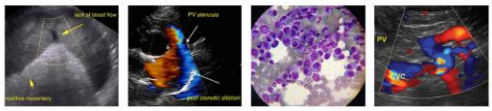

SonoPath
Clinical Sonography & Telecytology
EDUCATIONAL TELECONSULTATION SERVICES™
1-800-838-4268 info@sonopath.com SonoPath.com

PATIENT
Luna Borsa

SPECIES
Feline

BREED
Angora

SEX
Female Spayed

AGE
13 years

WEIGHT
12.8lbs

INTERPRETED BY
Maggie Machen Lamy, DVM DACVIM (Cardiology)

IMAGING PERFORMED BY
Pamela Harrigan, RDCS

HOSPITAL NAME
Wood River Animal Hospital

REFERRING VET
Dr. Schuelke

INVOICE
23401

DATE
4.1/22

PRESENTING CLINICAL SIGNS

History: Grade lll/Vl systolic murmur as well as arrhythmia noted on exam. BP: 165-170mmHg. Luna doing well clinically. *Sedated with butorphanol for study.

ELECTROCARDIOGRAPHIC FINDINGS *Note: Single lead ECGs are evaluated as a rhythm strip. Morphology/MEA cannot be definitively commented on.

A single lead ECG is available from an Alivecor phone monitor (50s duration 25mm/s and 10mm/mV). The underlying heart rate is reasonable; however, there are no 2 consecutive sinus beats identified. Frequent VPC's are seen throughout in a bigeminal rhythm. VPC's appear monomorphic. No couplets, triplets or runs of VT are appreciated.
ECG diagnosis: Ventricular bigeminy.

ECHOCARDIOGRAM FINDINGS

2D, m-mode, color flow and Doppler imaging is available.
Left ventricle: The LV diameter is normal with adequate function. The LV wall is highly asymmetric with an irregular septum with regions of thinning and a thickened free wall. There is a diffusely hyperechoic endocardium consistent with fibrosis. The papillary muscles are hypertrophied and hyperechoic. The endocardium appears remodeled.
Left atrium: The left atrium is mild to moderately dilated. No obvious smoke or thrombi seen.
Mitral valve: The mitral valve appears mildly thickened with mild central MR. No obvious systolic anterior motion is seen, although the tip of the mitral valve does exhibit abnormal motion.
Aortic valve/Aorta: The aortic valve is normal. No obvious stenosis. Normal aortic outflow velocity; laminar flow. Trace aortic insufficiency.
Right ventricle: Mild right ventricular dilation.
Right atrium: The right atrium is mildly dilated.
Tricuspid valve: The tricuspid valve appears mildly thickened with mild to moderate tricuspid regurgitation.
Pulmonic valve/Pulmonary artery: The pulmonic valve is normal in morphology and mobility. No pulmonic insufficiency. Normal RVOT velocity; laminar flow.
Pericardium/other: No pericardial or pleural effusion noted. No obvious cardiac masses.

2-Dimensional Measurements

Ao diam (cm)	1.0
LA diam (cm)	1.6
LA:Ao (Swe)	1.6
IVS thickness (cm)	0.31
LVID diastole (cm)	1.6
PW thickness (cm)	0.69
LVID systole (cm)	0.35
FS (%)	75

Doppler Measurements

PV Vmax (m/s)	1.1
AoV Vmax (m/s)	1.5
MR Vmax (m/s)	NM
TR Vmax (m/s)	NM
TR PG (mmHg)	NA

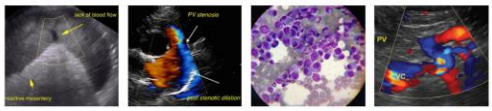

PATIENT
Luna Borsa

SPECIES
Feline

BREED
Angora

SEX
Female Spayed

AGE
13 years

WEIGHT
12.8lbs

INTERPRETED BY
Maggie Machen Lamy, DVM DACVIM (Cardiology)

IMAGING PERFORMED BY
Pamela Harrigan, RDCS

HOSPITAL NAME
Wood River Animal Hospital

REFERRING VET
Dr. Schuelke

INVOICE
23401

DATE
4.1/22

INTERPRETATION OF THE FINDINGS

The finding of mild to moderate left atrial enlargement in the face of a highly irregular LV is most consistent with end-stage HCM; however, UCM is also a possibility. Mild to moderate left atrial dilation is present in addition to a highly remodeled LV, which indicates diastolic dysfunction. The murmur is due to MR and TR, which should be monitored going forward. Finally, the ECG confirms ventricular bigeminy indicating every other beat is a VPC. VPCs in this case are certainly secondary to structural disease, likely exacerbated by stress.

Regardless of categorical classification, the finding of atrial dilation and arrhythmic disease confers risk for progression in the future and medications should be considered. Pimobendan is recommended given the totality of the findings. Additionally, Plavix may be reasonable given atrial dilation to help decrease the risk of a blood clot event in the future. If the patient is able to be medicated, these are recommended as below.

Additionally, we must determine if treatment is indicated for the arrhythmia. In an asymptomatic cat, it is reasonable to simply monitor going forward given only single VPCs identified. That being said, bigeminy puts the patient at higher risk for complications and/or sudden death in the future, and Atenolol is recommended as a conservative approach. Recommend reassess the ECG in 1-2 weeks.

The long-term prognosis given the totality of the findings is guarded; however, there is a highly variable rate of progression in cats with sub-clinical disease. There will always remain risk for progression to CHF and development of blood clots in the future. Monitoring is certainly advised, particularly should any respiratory signs, collapse or significant lethargy be noted in the future.

RECOMMENDATIONS

- If able, institute blood thinner Plavix 75mg tabs; Give ¼ tab by mouth every 24 hours (NOTE: bitter along cut edge, may cause foaming at the mouth; coat in entirety).
- If able, institute Pimobendan (off label use) 1.25mg PO q12h.
- Recommend institute Atenolol 25mg tablets; Give ¼ tab once daily. Recheck heart rate in 1-2 weeks with target stressed rate of 140-160bpm 12-24 hours post-administration. Increase as needed until target reached.
- If patient develops lethargy or collapse, immediate recheck ECG is recommended to screen for malignant sustained arrhythmias.
- Elective anesthesia is not advised.
- Monitor for any clinical evidence of cardiac compromise, including respiratory changes, collapse and/or signs of a blood clot event (paralysis, neurologic changes, etc.)

PLAN

- Recheck BP and ECG in 1-2 weeks, then every 3-4 months lifelong.
- Recheck echocardiogram in 6 months, sooner if clinical signs arise

PAUS
Pet Animal Ultrasound Service
4paus.com 781-635-5677

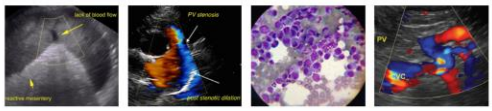

SonoPath
Clinical Sonography & Telecytology
EDUCATIONAL TELECONSULTATION SERVICES™
1-800-838-4268 info@sonopath.com SonoPath.com

PATIENT
Luna Borsa

SPECIES
Feline

BREED
Angora

SEX
Female Spayed

AGE
13 years

WEIGHT
12.8lbs

INTERPRETED BY
Maggie Machen Lamy, DVM DACVIM (Cardiology)

IMAGING PERFORMED BY
Pamela Harrigan, RDCS

HOSPITAL NAME
Wood River Animal Hospital

REFERRING VET
Dr. Schuelke

INVOICE
23401

DATE
4.1/22

IMAGES

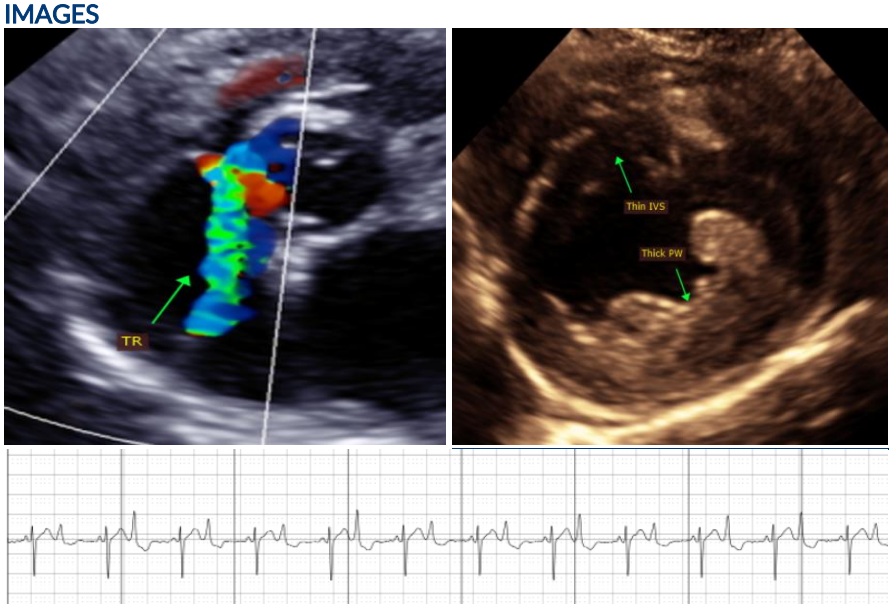

The information and recommendations provided are based on the images presented by the referring veterinarian. No evaluation can be communicated regarding pathology that was not visible in the image/video clips provided.

Thank you for this referral. This report was generated using transcription software, and minor dictation errors may be present. If the clinical or image interpretation does not parallel your findings or if I can be of any further assistance, please contact me.

Maggie Machen Lamy, DVM
Diplomate of the American College of Veterinary Internal Medicine (Cardiology)
info@sonopath.com